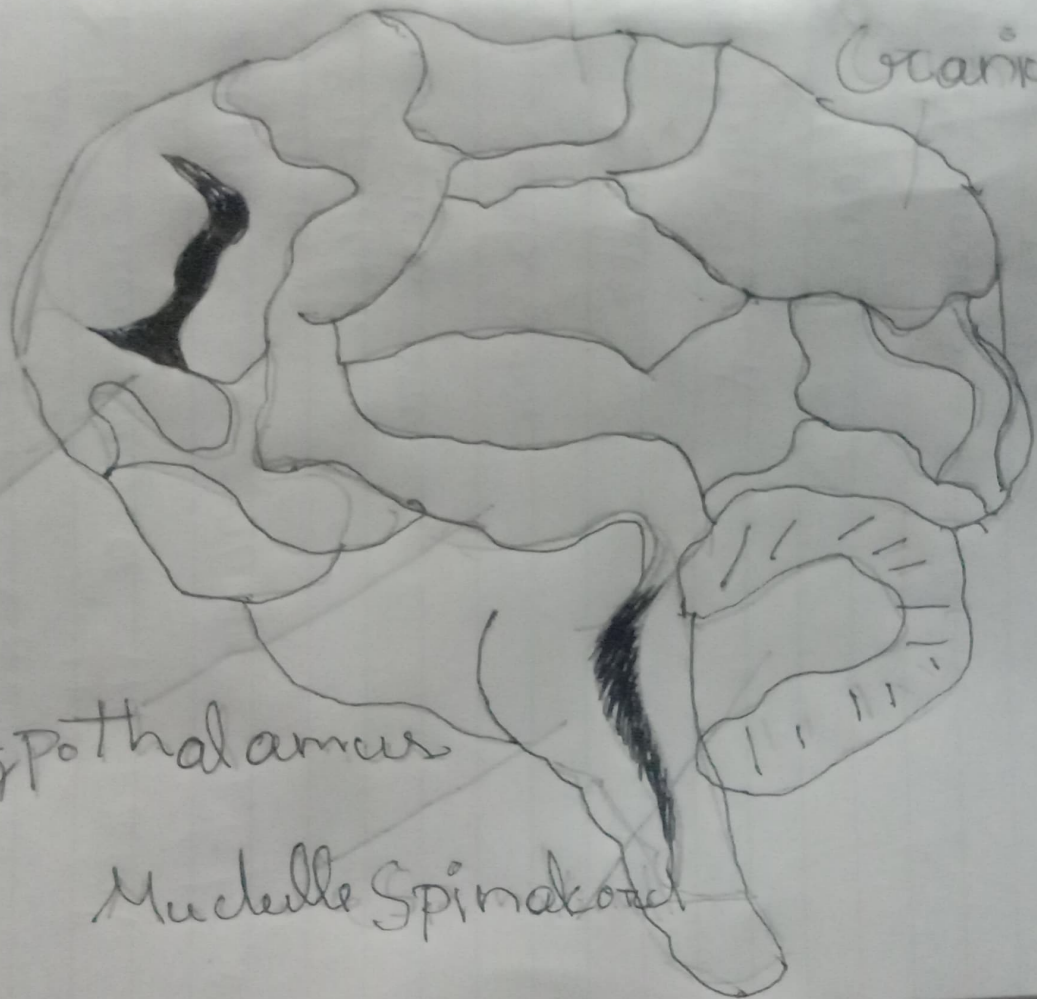


Cerebrum

Cranium (Skull)



Hypothalamus

Nucleus Spinakord