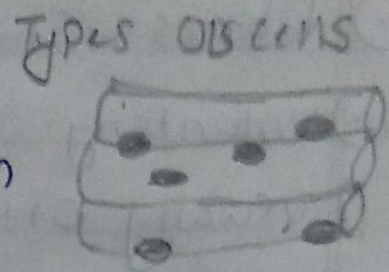


MUSCLE


1) **Skeletal Muscle**  
(near bones)

**Characteristic**  
 → Voluntary  
 → usually attached to skeleton



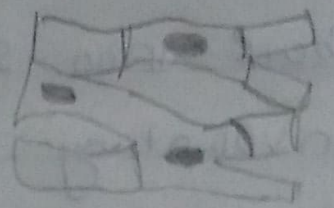**Smooth Muscle**  
(Stomach, small & large intestine)

→ Involuntary  
 → covering wall of internal organs



**Cardiac Muscle**  
(Heart)

→ Involuntary  
 → covers walls of heart



2) **Structure of a typical neuron**

