

Name: Sashwat Bradhan Date: 21/08/2023
 Age: 2y Sex: M
 HT: WT: 40kg HC:



40 - Pain abdomen

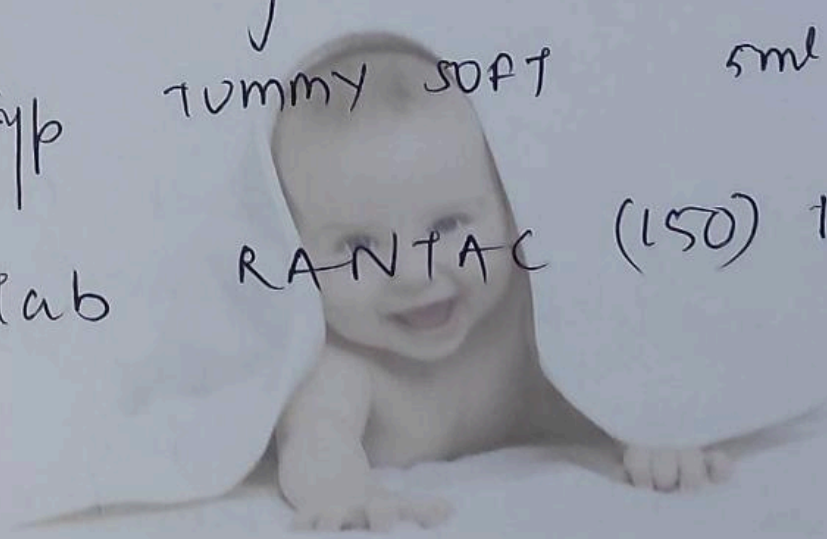
Bilirubin on defecation

Δ- IBS (ruid)

① Diet monitoring — trigger identification

② Syb Tummy soft 5ml twice x 5d

③ Tab RANTAC (150) 1 ——— 1 x 10d



Signature: *A right place for the right care...*

FOR APPOINTMENT & ALL PATHOLOGY TEST COLLECTION CONTACT

 **7008258062, 9938152564**

① Probiotic rich food -

② Home food - strict avoid
fried / refined / process food /

③ weight - obese -

④ water 3L/day

01/08/23 this

is to certify ~~Sashwat~~ Pratham
Pratham Pratham, is examined by me
and diagnosed as case of functional GI
disorder (irritable Bowel syndrome). Child
is strongly advised to take home base
whole grain food and regulate water
and sleep. For further queries I may
be contacted at 9439035260.
Dr. Palash Das

DR. PALASH DAS
MBBS, M.D. (PEDIATRICS) PDF
Regn. No. - 16529/2007
Date:



MAX DIAGNOSTIC PVT. LTD.

Ranihat, Medical Road, Cuttack - 753007, Ph.: 0671-2425400, 2424500

AN ISO 9001 : 2008 CERTIFIED

Name : Mr. Saswat Pradhan

Ref. by : Dr. A. C. Parija

Age : 7Yrs, Sex : M

Date : 08.06.2023

FULL ABDOMEN SONOGRAPHY

LIVER : The liver is normal (11.0cm) in size and shows homogenous normal parenchymal echotexture. No focal lesion seen. The hepatic vessels are normal. IHBR – not dilated.

GALL BLADDER : The gall bladder is well distended and shows normal wall thickness. There is no evidence of calculus or mass seen. There is no peri-cholecystic collection seen.

COMMON BILE DUCT : It is normal in course and caliber.

PORTAL VEIN : It is normal in course & caliber.

PANCREAS : The pancreas is normal in size and shows homogenous parenchymal echotexture. No focal lesion is seen. Pancreatic duct not dilated.

SPLEEN : It is normal (7.9cm) in size, shape & echotexture. There is no focal lesion seen. The splenic vein at hilum is normal.

KIDNEYS : Both kidneys are normal in size, shape and position. No calculus or hydronephrosis seen in right kidney. No calculus or hydronephrosis seen in left kidney. Cortico-medullary differentiation is maintained.

RK- 80x32 mm

LK- 85x34mm

URETERS: Both the ureters are not dilated & hence not seen sonographically.

URINARY BLADDER : The urinary bladder is distended. The bladder wall thickness is normal. There is no evidence of any mass lesion or calculus seen.

PROSTATE : Visible.

REST OF ABDOMEN :

There is no para-aortic lymphadenopathy.

There is no free fluid noted in the abdomen.

Appendix not visualized.

IMPRESSION : NORMAL USG STUDY.

SUGGESTED : CLINICAL CORRELATION.

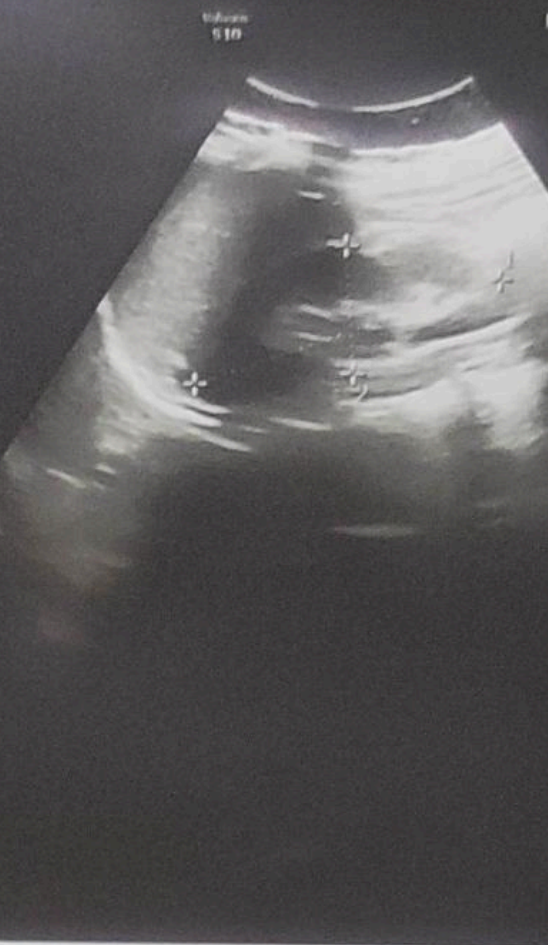
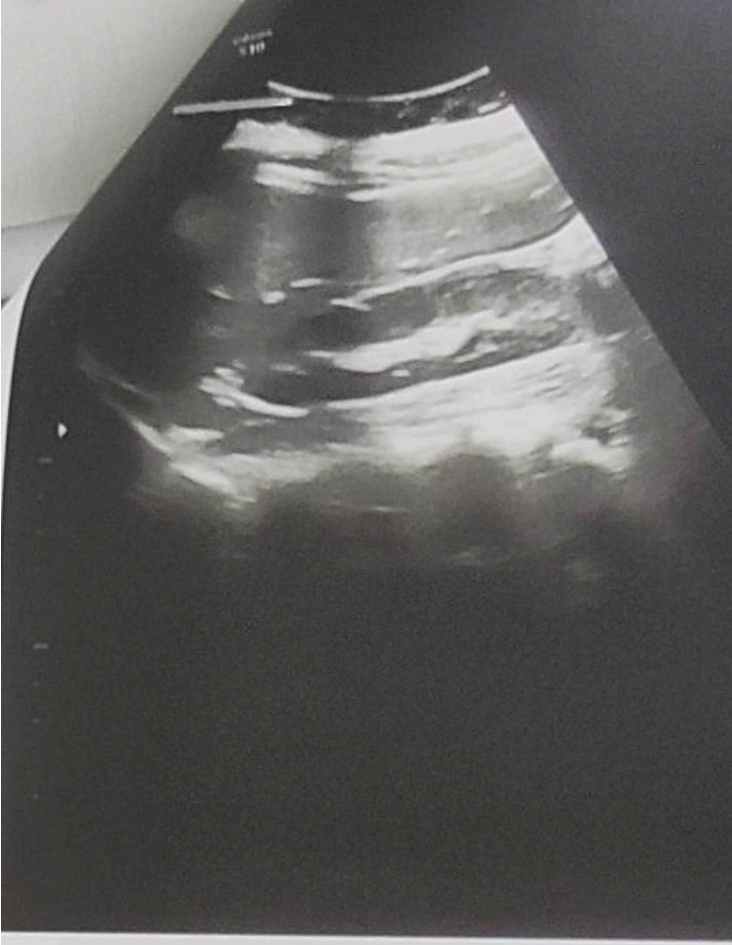
DR. SANJEEB KU. DEEP, M.D (R.D).
RADIOLOGIST

MAX DIAGNOSTIC PVT.LTD.

08.06.2023 10:48:57 AM

TIs <0.1
TIB <0.1
MI 1.0

CI 5 RS
ABD
19.5cm / 1.1
64° / 20Hz
Abdomen 1
HM PI 7.70 2.10
AO 98%
Gn 3
C6 / M8*
FF2 / E2
SRI II 3 / CRI 2



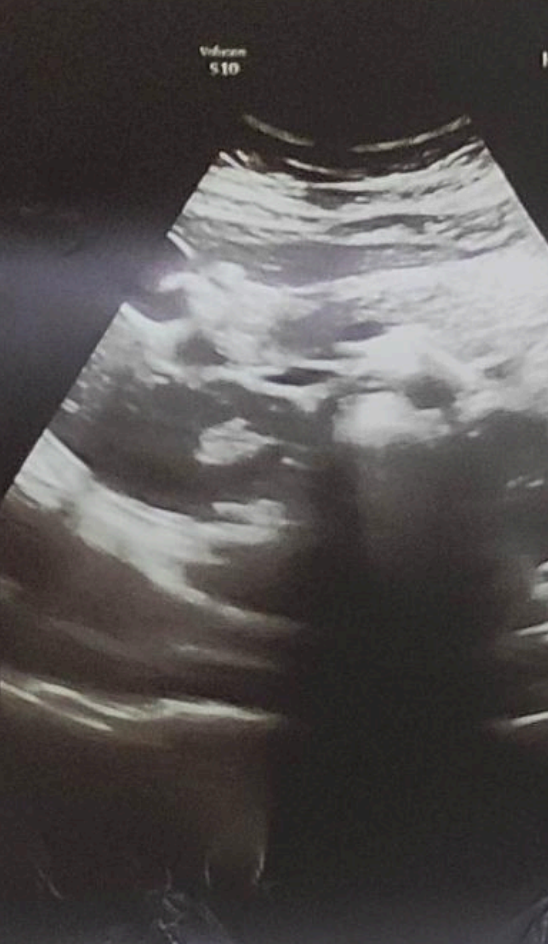
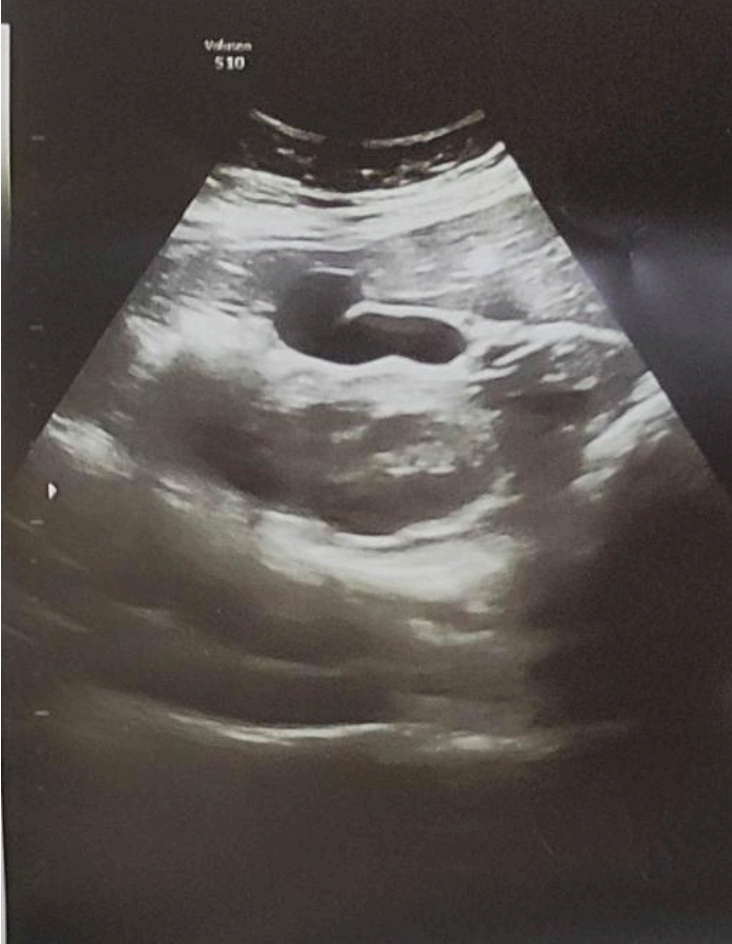1D 8.51cm
2D 3.43cm

MAX DIAGNOSTIC PVT.LTD.

08.06.2023 10:48:25 AM

TIs <0.1
TIB <0.1
MI 1.0

CI 5 RS
ABD
19.5cm / 1.1
64° / 20Hz
Abdomen 1
HM PI 7.70 2.10
AO 98%
Gn 2
C6 / M8*
FF2 / E2
SRI II 3 / CRI 2



Dr. A.C. Parija, M.D.

Common Wealth Fellow Neonatology (U.K.)

Ex-Professor & HOD, Paediatrics

S.C.B. Medical College, Cuttack

&

MKCG Medical College, Berhampur

CONSULTING HOURS

Morning : 8.00 am to 12 Noon

Kalyani Nagar


☎ : (0671) 2344300

ଝାଞ୍ଚି ଚାଲି

Name : Saswat Pradhan Date : 07/06/23
Age..... 7yr Weight..... 40kg

- Rx (1) Lanzaal-30 in Dose = 15T
- (2) Sucraven-0 sly
- (3) ~~Dostin-40~~ the sas
- (4) Prostectin- 12 sach = 10T.

8/6/23
Ultra Sound of Abdomen
KG

20/8/23
→ Dostin 88 & 18ml 38
→ Turns soft sly 2kg


Dr. Debasis Jena

Assistant Professor

M.B.B.S, MS ENT & Head & Neck Surgery

Trained in Endoscopic Sinus & Ear Surgery, Microscopic Ear Surgery

Thyroid & Laryngeal diseases

Regd. No. : 17556 (OCMR)



Name : Shashwat Pradhan Age/Sex : 7 M Weight 30kg Date : 31/03/23

R

flop adenoid hypertrophy
c OME @ ear

Adv
→ Impedance { (R) 'A' } (L) 'A' } Pt 'A' type

PTA { (R) 28 } (L) 27

1

Tab L-Montus kid Forli-

OD BT in evening x 1month-

2

Fluticone-FT nasal spray

1 puff BID x 1month

31/03/23



Dr. Jena ENT Clinic

Plot No : 626, Maharshi College Road, Saheed Nagar, Bhubaneswar

Mobile : 9937778244, E-mail : drdebasisent@gmail.com

Dr. Debasis Jena

Assistant Professor

M.B.B.S, MS ENT & Head & Neck Surgery

Trained in Endoscopic Sinus & Ear Surgery, Microscopic Ear Surgery

Thyroid & Laryngeal diseases

Regd. No. : 17556 (OCMR)



Name : Shashwat Pradhan Age/Sex : 7 M Weight 39 kg Date : 06-02-23

R

Adv
Nasal Endoscopy

Δ Adenoid hypertrophy i AM Deal

① FLUTICONE-0X Nasal Spray
1 puff BD x 10 days
↓
Stop

② Fluticone-FT Nasal Spray
1 puff BD x 1 month

③ Tab Montek-LC Kid OD BF
in evening x 1 month

6/2/23

Dr. Jena ENT Clinic

Plot No : 626, Maharshi College Road, Saheed Nagar, Bhubaneswar
Mobile : 9937778244, E-mail : drdebasisent@gmail.com

Δ Adenoid hypertrophy c OME (Dea)

18F
① Tab Cotrimox / Defecord (6mg)

OD 18F x 14 days

0
② 18F Tab Junior Lanzole (30mg)

OD 18F x 20mg


8
③ Tab

L-Montel kid forte

OD 18F x 1 month
in evening

④ Continue

fluticome-FT nasal spray
1 puff BD


28/2/22