

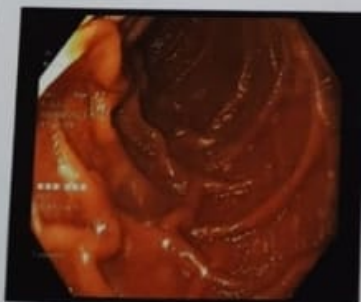
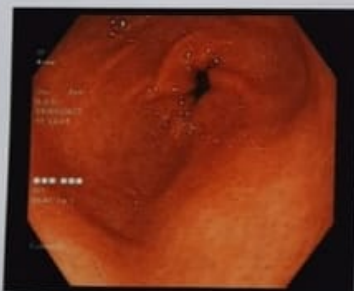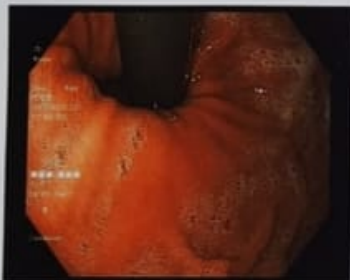
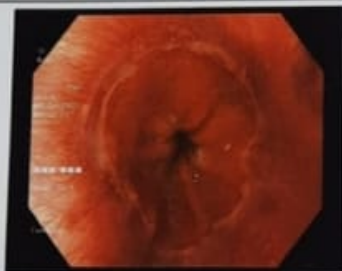APOLLO HOSPITAL

Plot No:251, Sainik School Road, Unit-15
Bhubaneswar-751005

Tel: 0674 6661066/6661016 Fax: 0674-6660408

Patient ID: 2023090117
Name: Mr. SUBHAM SAHU
Age: 16 Y
Sex: M
Date: 30-Oct-2023

Ref By: Dr. SUSHANT KUMAR SETHI ,MD
(Medicine),DNB(GASTRO)
Study: UGI ENDOSCOPY
Examined By: Dr. SUSHANT KUMAR SETHI
,MD(Medicine),DNB(GASTRO)
Hospital ID: ODB1.0000805650



REPORT OF UPPER G.I ENDOSCOPY

INDICATION : Pain abdomen, early satiety, dyspepsia.

PREMEDICATION : Xylocaine spray

OESOPHAGUS : Normal.

G.E JUNCTION : 40 cm, from incisor teeth.

STOMACH :

FUNDUS : Hiatus hernia seen on retroversion

BODY : Erythematous mucosa with few erosions seen

ANTRUM : Erythematous mucosa with multiple erosions seen

PYLORUS : Normal

DUODENUM:

1ST PART : Normal

2ND PART : Normal

RUT : Done

IMPRESSION : **HIATUS HERNIA.**
EROSIVE GASTRITIS.



Dr. SUSHANT KUMAR SETHI
,MD(Medicine),DNB(GASTRO)